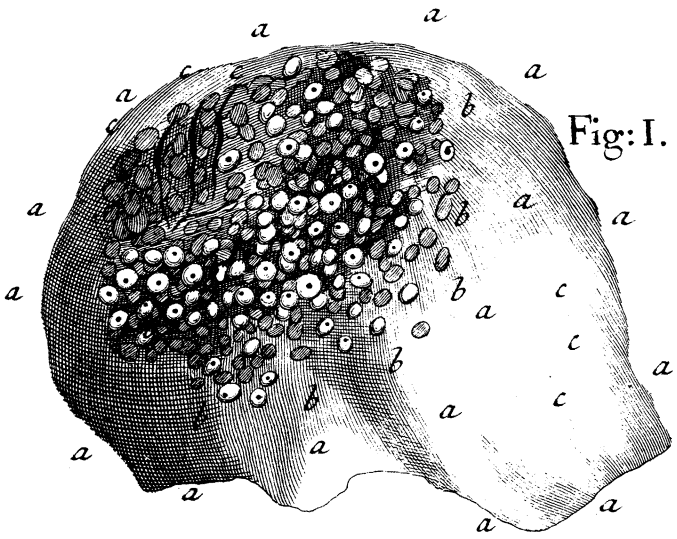

Fig: I.

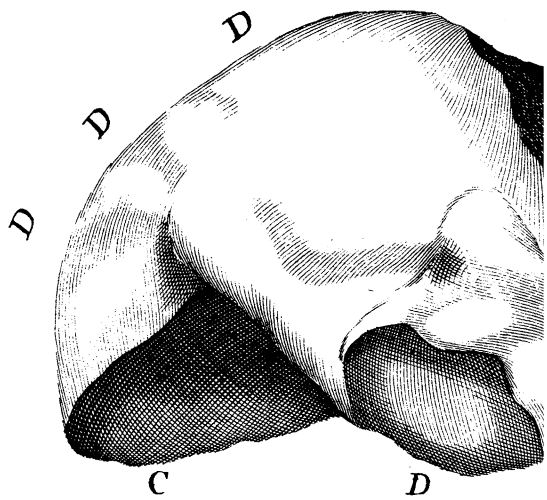

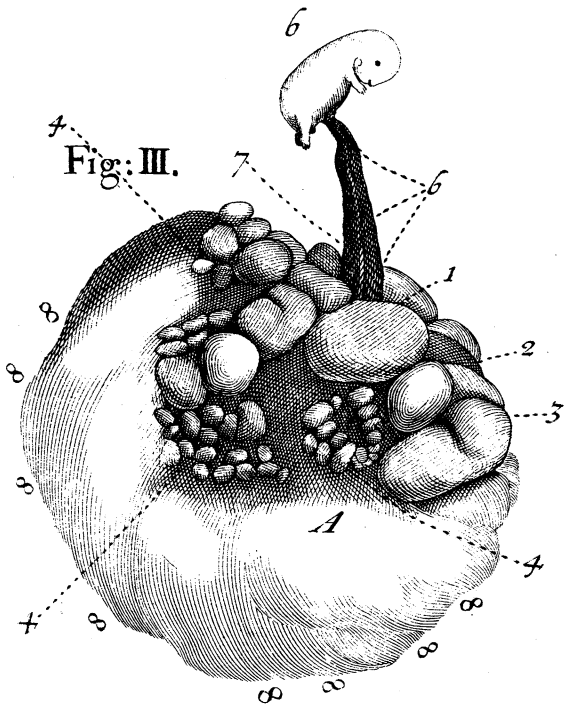

Fig: III.

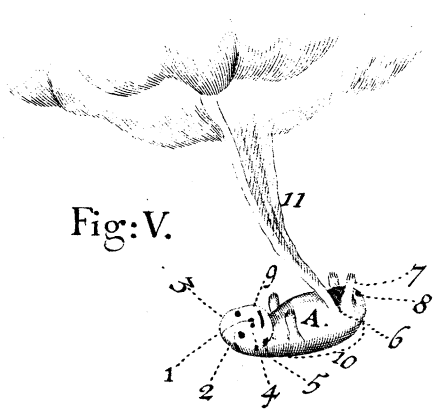

Fig: V.

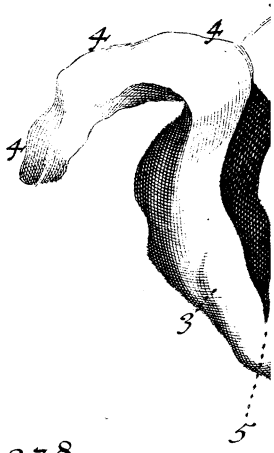

Philosoph: Transact: No. 238.

The Royal Society is collaborating with JSTOR to digitize, preserve, and extend access to *Philosophical Transactions (1683-1775)*.
www.jstor.org

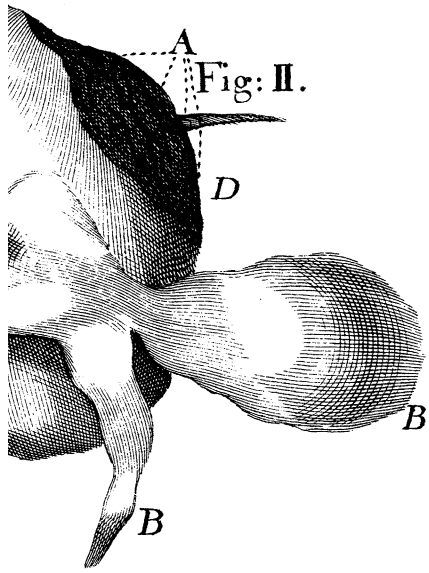


Fig: II.

Fig: IIII.

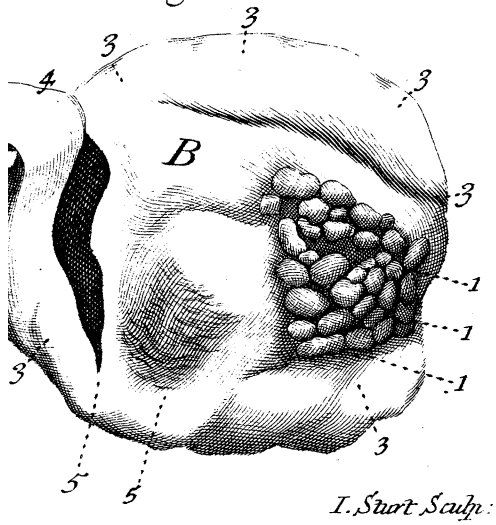


I. Stuart Sculp:

*the Royal Society by the Right Honourable Sir* Rob Southwell, *V.P R.S.* VII. *An Account of a very large Eel, lately caught at* Maldon *in* Eſſex; *with ſome Conſiderations about the Generation of Eels, by Mr.* Dale. IX. Account of a Book. *The Hiſtory of* Poland *in ſeveral Letters to Perſons of Quality, giving an count of the Ancient and Preſent* State *of that* Kingdom, Hiſtorical, Geographical, Phyſical, Political *and* Eccleſiaſtical, *&c. With ſeveral Letters relating to Phyſick.* Vol I. *To which is added a new Map of* Poland. *By* Bern. Connor, *M.D. F.R.S. and Member of the Colledge of Phyſicians*, &c.

---

I. *Hiſtoria ; & explicatio figurarum, Embryon quatuor Septimanarum, & placentam cotiledoniformen exhibentium, Autore Philippo Jacobo Hartmanno,* Phil. & Med. D. *&c.*

MAtrona quadraginta circiter annorum, *tertium* hunc *abortum* faciebat, anno 1685. *Septemb.* 27. ante quatuor Septimanas ipſi menſes adhuc fluxerant, tertio autem qui abortum præceſſit die linteis lævigandis operam navans, & cylindris ducendis manum admovet, exin die dicto ſanguis grumoſus magnâ copiâ erumpere, quum alias Uteri hæmorrhagiæ eſſet obnoxia; ſucceſſit tandem placenta cum chorio, amnio & fœtu formâ ovi integri; quod ovum citra ullam aliorum contractationem ac palpationem domum auferre licuit, ubi otioſus omnia rimatus ſum.

Figura

## Figura I.

*Placentæ ſtructuræ exterioris, quâ Utero adhæſit, partem Colyledoniformem exhibens.*

a a a &c. Magnitudo placentæ, quæ totius Uteri cavitatem implevit.

b b b &c. Pars cotyledoniformis meris glandulis globoſis obſita; glandulæ in medio rubicunda puncta oſtendunt vaſorum ruptorum ora hiantia: circa puncta ſunt foveolæ quaſi impreſſæ, quas & ſceleton monſtrat: Huic parti colytedoniformi intus oppoſitæ erant veſiculæ rubicundo & flavo liquore diſtentæ, quas figura III. exprimit.

c c c Loca in quibus ſanguinei ductus inſigniter erant conſpicui.

## Figura II.

*Placentæ Structuræ exterioris, quâ Utero adhæſit, partem alteram exhibens.*

A. Locus ex quo vaſa longiora avulſa dependebant; ubi Placenta Utero firmius annexa aut agglutinata fuit.

B. B. Laciniæ Placentæ gracileſcentis.

C. Foramen per quod Chorion & amnion prominebant.

D. D. &c. Placentæ globus quem omnes figuræ repreſentant, ut totius Uteri cavitatem à Placenta ſuccinctam fuiſſe, fœtumque in eadem tanquam in altero Utero ſive Utriculo contineri conſtet.

## Figura III.

*Placentæ Structuræ interioris pars prior cum Embryo.*

1. Veſicula inſignior ſanguine rubicundo turgida.

2. Veſicula alia flavo liquore repleta.

3. Veſicula maxima ibidem flavo liquore diſtenta.

4. 4. 4. 4. Veſiculæ circum ſitæ minores, variâ proportione, varioque liquore, rubicundo, flavo, limpido, plenæ.

5. Umbilicalis funiculus cum vaſis.

6. Embryon; figuræ, magnitudinis, manuum & pedum

dum ſitûs, penis, podicis caudati, foraminis ani quaſi à meconii nigrore punctati, helices auriculæ, rectûs oris, accuratâ omnium delineatione.

7. Locus in quo funiculi tunica veſicularum latebris ſe inſinuabat.

8.8.8. *&c.* Spatium veſiculis vacuum, chorio & amnio Placentæ crepidinibus annexis.

Figura IV.

*Placentæ Structuræ interioris pars altera ſine Embryo.*

1.1. 1. Veſicutæ variâ magnitudine, varioque in eis liquorum colore.

2. Vaſa ſanguinea hinc inde commeantia.

3. 3. 3. *&c.* Spatium Veſiculis vacuum, Placentæ expanſionem cum annexa Chorii tunica oſtendens.

4. 4. 4. Lacinia Chorii cum Placentæ divulſæ parte graciliori.

5. Foramen à Placentæ & Chorii ruptura.

Figura V.

*Embryon exhibens.*

A. Embryi Corporis habitudo.

1. Linea alba frontem dividens.

2. 3. Duæ aliæ lineæ albæ ad futuram coronalem tendentes.

4. Duo puncta quæ narium foramina deſignant.

5. Helix auriculæ albicante lineâ diſcreta.

6. Penis.

7. Pedum digiti inequaliter deſinentes, cum exiguis lineis fiſſurarum indicibus; eadem ratio manuum.

8. Caudæ eminentia cum punctato ani foramine.

9. Oris rictus.

10. Medulla ſpinalis albicans utrinque à ſe verſus latera exiles lineas albas, æqualiter curtas, dimittens.

11. Umbilicalis funiculus per cujus tunicam exilia vaſa tranſparent.

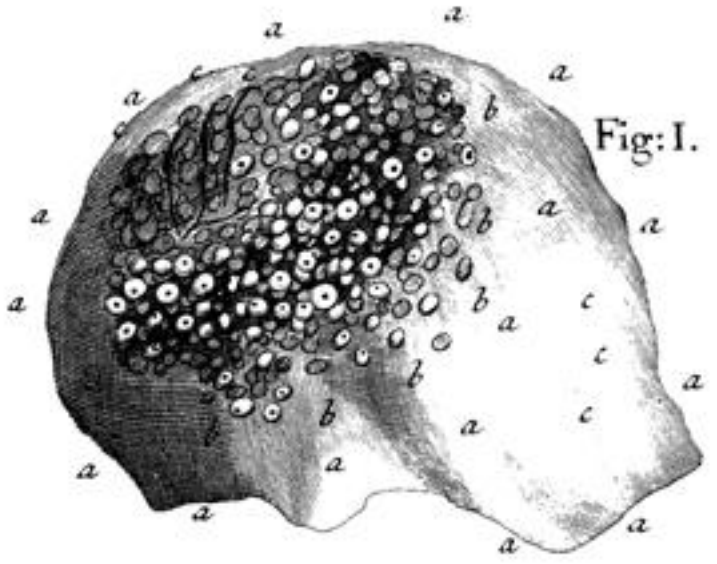


Fig: I.

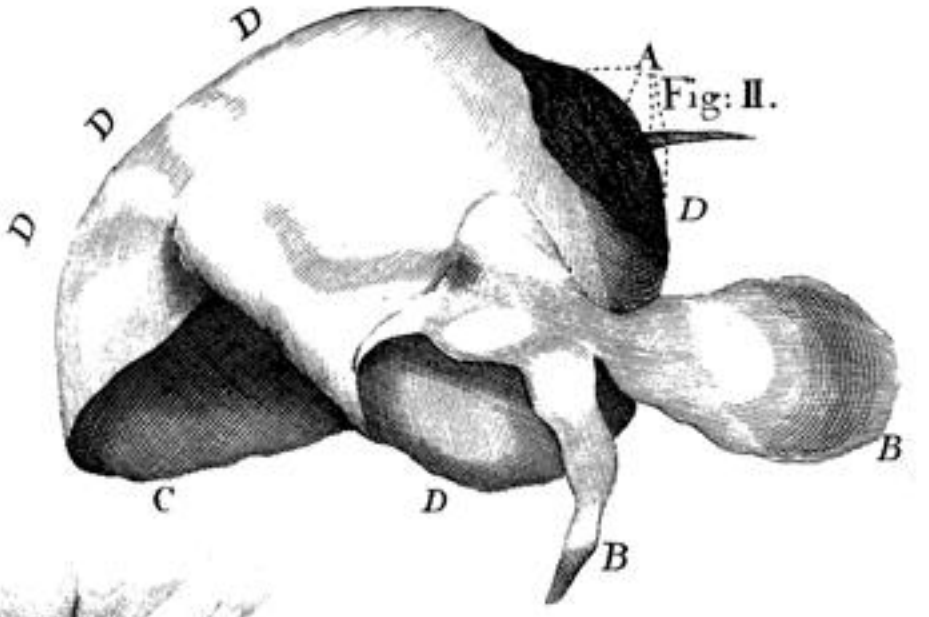


Fig: II.

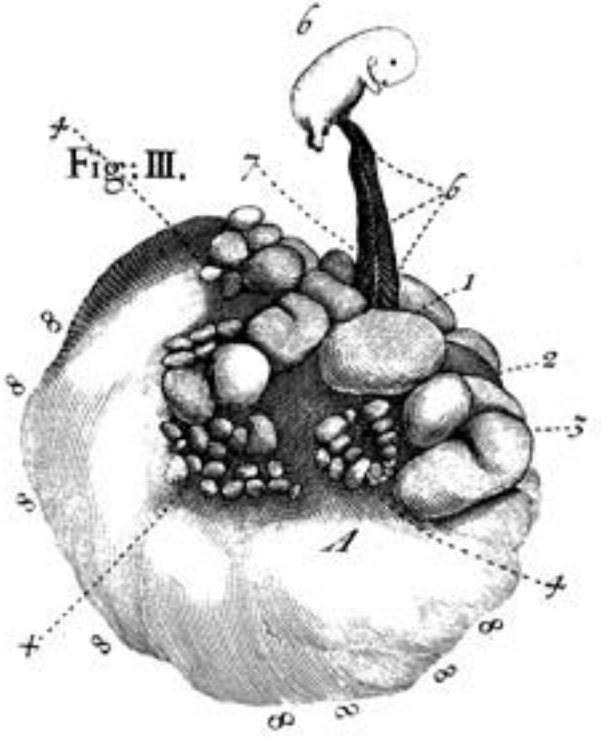


Fig: III.

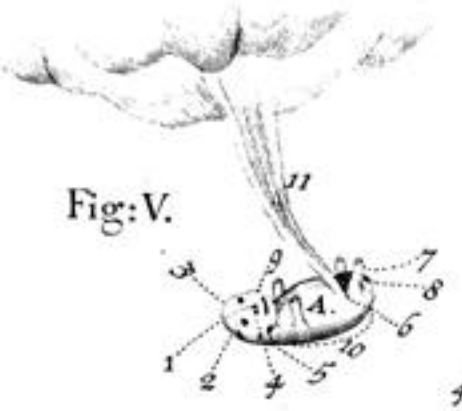


Fig: V.

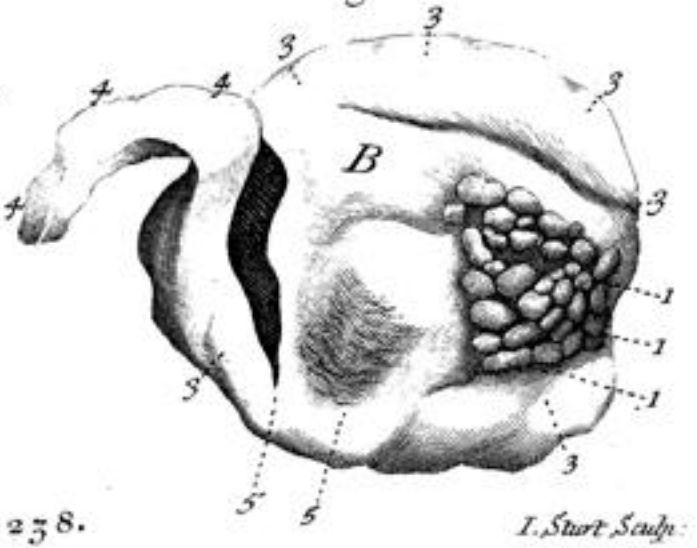


Fig: IIII.



I. Sturt Sculp: